



## Diabetic Foot Wound

---

**Said Atway, DPM, FACFAS**  
*Associate Professor-Clinical  
Department of Orthopaedics  
The Ohio State University Wexner Medical Center*

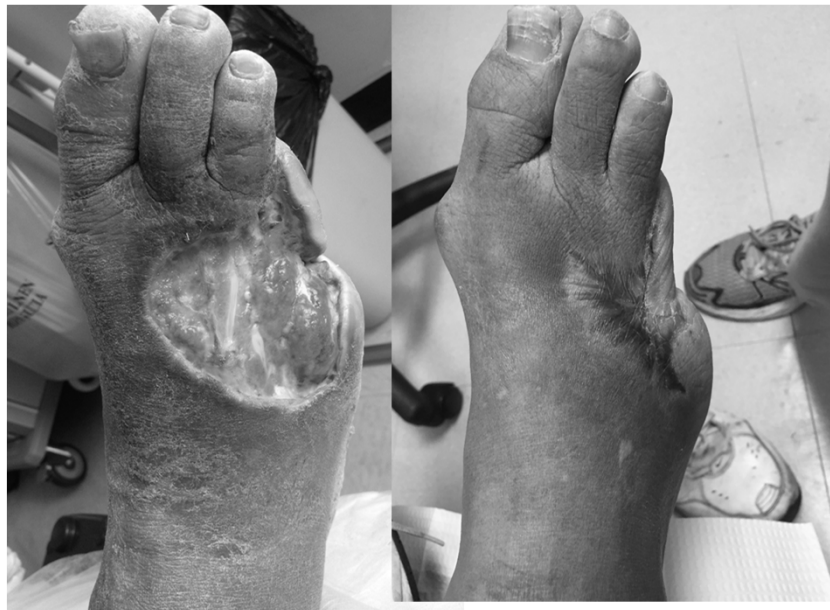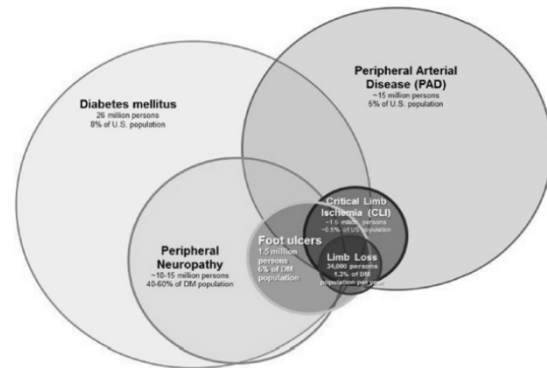
**MedNet21**  
Center for Continuing Medical Education

 **THE OHIO STATE UNIVERSITY**  
WEXNER MEDICAL CENTER

“Diabetic foot” variety of  
pathological conditions that  
might affect the feet in patients  
with diabetes (Boulton 2002)

## Team Approach

- Expedited referral and care
- Madagin program proven to decrease amputations 82%
  - Driver et al. Diabetes Care 2005
- Swedish study decreased amputations 71% over 11 years
  - Wennberg et al Diabetes research 2019
- UK study 40% reduction and 62% reduction in major amputations



## The management of diabetic foot: A clinical practice guideline by the Society for Vascular Surgery in collaboration with the American Podiatric Medical Association and the Society for Vascular Medicine

Anil Hingorani, MD,<sup>a</sup> Glenn M. LaMuraglia, MD,<sup>b</sup> Peter Henke, MD,<sup>c</sup> Mark H. Meissner, MD,<sup>d</sup> Lorraine Loretz, DPM, MSN, NP,<sup>e</sup> Kathya M. Zinszer, DPM, MPH, FAPWCA,<sup>f</sup> Vickie R. Driver, DPM, MS, FACFAS,<sup>g</sup> Robert Frykberg, DPM, MPH, MAPWCA,<sup>h</sup> Teresa L. Carman, MD, FSVM,<sup>i</sup> William Marston, MD,<sup>j</sup> Joseph L. Mills Sr, MD,<sup>k</sup> and Mohammad Hassan Murad, MD, MPH,<sup>l</sup> *Brooklyn, NY; Boston and Worcester, Mass; Ann Arbor, Mich; Seattle, Wash; Danville, Pa; Providence, RI; Phoenix Ariz; Cleveland, Ohio; Chapel Hill, NC; Houston, Tex; and Rochester, Minn*

**Background:** Diabetes mellitus continues to grow in global prevalence and to consume an increasing amount of health care resources. One of the key areas of morbidity associated with diabetes is the diabetic foot. To improve the care of patients with diabetic foot and to provide an evidence-based multidisciplinary management approach, the Society for Vascular Surgery in collaboration with the American Podiatric Medical Association and the Society for Vascular Medicine developed this clinical practice guideline.

**Methods:** The committee made specific practice recommendations using the Grades of Recommendation Assessment, Development, and Evaluation system. This was based on five systematic reviews of the literature. Specific areas of focus included (1) prevention of diabetic foot ulceration, (2) off-loading, (3) diagnosis of osteomyelitis, (4) wound care, and (5) peripheral arterial disease.

**Results:** Although we identified only limited high-quality evidence for many of the critical questions, we used the best available evidence and considered the patients' values and preferences and the clinical context to develop these guidelines. We include preventive recommendations such as those for adequate glycemic control, periodic foot inspection, and patient and family education. We recommend using custom therapeutic footwear in high-risk diabetic patients, including those with significant neuropathy, foot deformities, or previous amputation. In patients with plantar diabetic foot ulcer (DFU), we recommend off-loading with a total contact cast or irremovable fixed ankle walking boot. In patients with a new DFU, we recommend probe to bone test and plain films to be followed by magnetic resonance imaging if a soft tissue abscess or osteomyelitis is suspected. We provide recommendations on comprehensive wound care and various débridement methods. For DFUs that fail to improve (>50% wound area reduction) after a minimum of 4 weeks of standard wound therapy, we recommend adjunctive wound therapy options. In patients with DFU who have peripheral arterial disease, we recommend revascularization by either surgical bypass or endovascular therapy.

**Conclusions:** Whereas these guidelines have addressed five key areas in the care of DFUs, they do not cover all the aspects of this complex condition. Going forward as future evidence accumulates, we plan to update our recommendations accordingly. (*J Vasc Surg* 2016;63:3S-21S.)

### • Prevalence

–29.1 Million people 9.3% of the US 2012

- CDC

–2.8% Worldwide 2000 (171 million)

- WHO

### Amputations

–73,000 non-traumatic amputations in diabetics 2010

- CDC

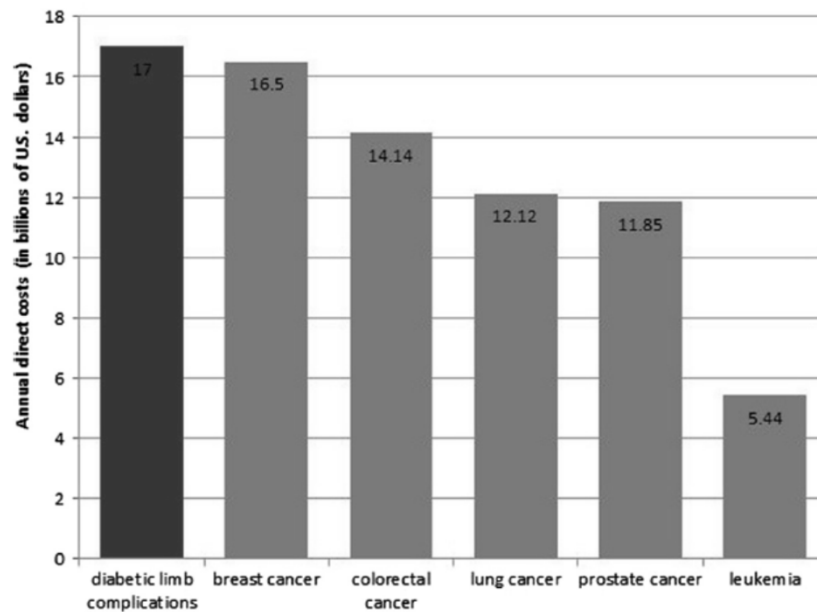
### –Cost

- \$4,595 per ulcer and \$28,000 >2years

- \$5billion per year annually

- *Clin Ther* 1998

- \$30-50k amputation according to president



## Foot Infections

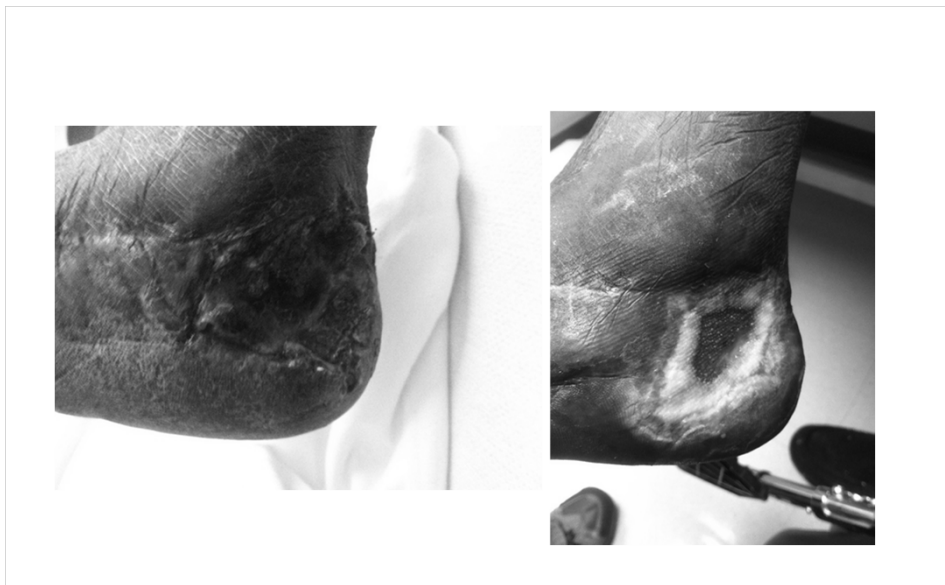- Any infra-malleolar infection in a person with diabetes
- Common and costly problem
  - DM related amputation cost 3B per year
    - *Diabetes Care 2003*
- Most common reason for a diabetic to be admitted
  - *National Hospital Discharge Data*
- Most common non-traumatic cause of amputation
  - 60% of LEA
  - Most common cause of nontraumatic lower extremity amputation
    - *Lancet 2005*





## Importance of Diabetic Wound care

- Diabetic foot ulcers present >4 weeks have a 5 fold higher risk of infection
- Infection in a foot ulcer increases the risk for hospitalization 55.7 times and risk for amputation 155 times
- 5 year mortality after limb amputation is 68%
  - *NIH publication 1995*



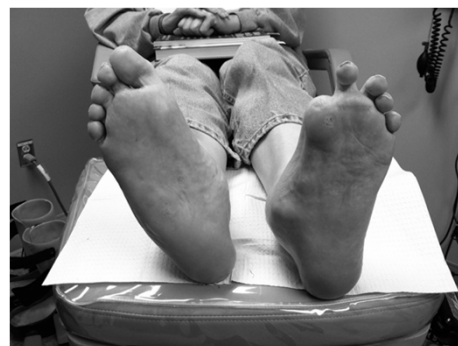The FDA defines a healed wound as reepithelialized skin without drainage or dressing requirements confirmed at 2 consecutive visits 2 weeks apart.

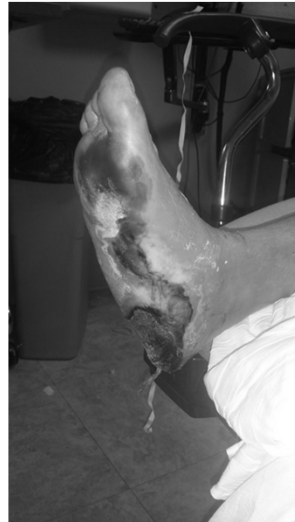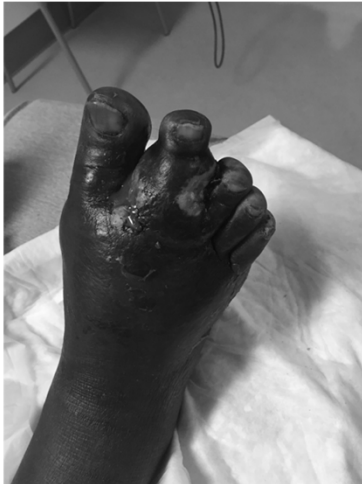---

## Guidance for Industry Chronic Cutaneous Ulcer and Burn Wounds – Developing Products for Treatment

### Clinical Practice Guidelines


- Management of etiologic factors
  - Adequate perfusion
    - PAD (Twice as common in DM)
    - Gregg et al 2004
 Rarely lead to ulcer directly  
 Contributes to 50% of ulcers  
*Diabetes Metab 2008*
  - Debridement
    - Sharp debridement of infection
    - Urgent for gas/necrotizing infection
  - Infection Control
    - IDSA guidelines
  - Pressure Mitigation
    - Offloading
    - Total contact cast





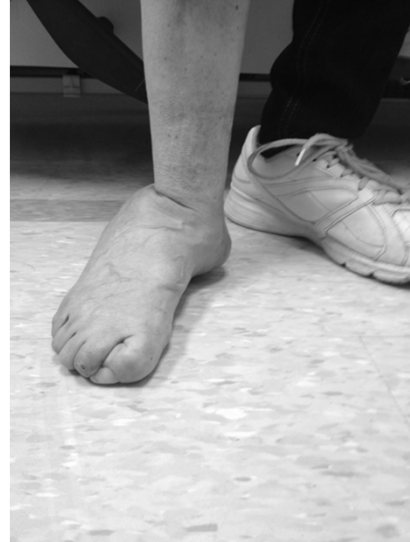## Vascular work up

- ADA recommendations:
  - ABI >50y DM
  - <50y with risk factors
    - Smoking
    - HTN
    - Hyperlipidemia
    - >10years DM
  - Anyone with PAD symptoms
- Dependent rubor
- Pallor on elevation
- Absence of hair growth
- Dystrophic nails
- Cool/Dry/Fissured skin
  - Diabetes Care 2003



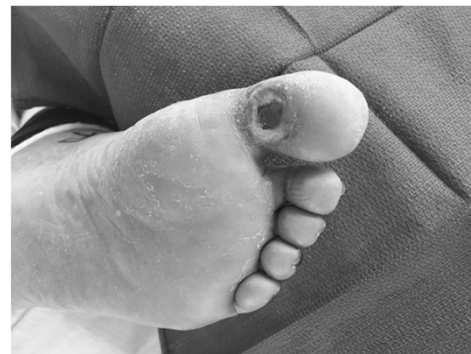# Deformity

- Pathophysiologic mechanism complex
  - Neuropathy
  - Repetitive trauma
  - Focal tissue ischemia
  - Tissue Destruction
- Foot deformities
  - Charcot
    - Neuroarthropathy
- Limited joint mobility
  - Glycosylation of soft tissue



# Wound Evaluation

- Size
  - % reduction early predictor of outcome
- Location
  - WB surface
  - Digits
  - Heel
  - Legs
- Shape
  - Margolins
- Depth
  - Deep tissue involvement
- Base
  - Necrotic/Fibrotic/Granular
- Border
  - Abnormal
- Probe
  - 89% Probe to bone
- Xrays
  - Free air/foreign body
- Infection
  - Advanced imaging work up





# Orthopaedic Wound Care

## Management of osteomyelitis and bone infection

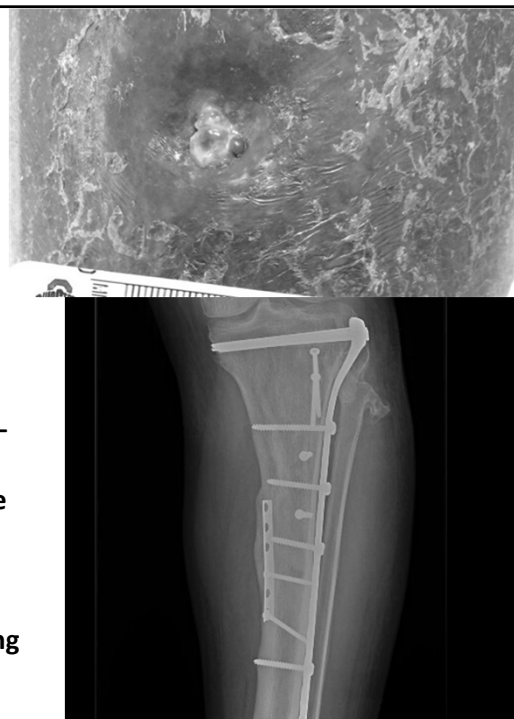
**Anne Sullivan, MD**  
*Assistant Professor - Clinical  
 Department of Orthopaedics  
 The Ohio State University Wexner Medical Center*

**MedNet21**  
 Center for Continuing Medical Education

**THE OHIO STATE UNIVERSITY**  
 WEXNER MEDICAL CENTER

## Why Orthopaedic Wound care?

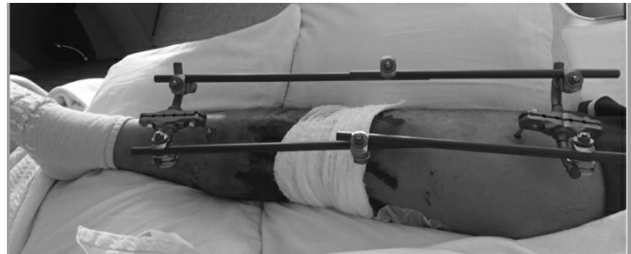- Things may not be as they appear.....
- Bone Expertise provides a margin for safety
- Bone Debridement without Expertise
  - May Compromise Structural integrity
  - May Fail to Eradicate infection
- Bone Debridement without Coverage
  - Exposes previously Protected area to Environment
  - May Promote Deeper Infection
- Biopsy techniques Must Avoid Contaminating deeper bone – Metaphyseal or Medullary bone.
- Red flag: Persistent Draining Wound despite Meticulous care
- What Lies Beneath.....
  - As many as 64% Diabetic Foot infections involve Bone
  - Foreign material and Necrotic bone harbor Biofilm
  - Granulation tissue Obscures, does Not Protect underlying Structures from Environment
  - Proper use of Imaging/X-rays is Essential



# Osteomyelitis

= Infection involving bone

- **Timing:** acute or chronic
- **Organisms:** *Staphylococcus aureus*
  - Most common, can be any organism
- **Causes/ examples:** (may be acute or chronic)
  - **Direct contamination – bone contacts environment—**
    - Open Fracture
    - Penetrating Trauma
    - Stage 4 ulcer
    - Animal or Human bite
  - **Contiguous spread –from Local wound or abscess,**
    - Diabetic Foot wound, Pressure ulcer, Paronychia, Injection Related abscess
    - Infected Fixation Hardware or Prosthetic Joint Infection (PJI)
  - **Hematogenous seeding from Remote source**
    - Endocarditis, Pyelonephritis,
    - Infections related to Injected Drug use



# Osteomyelitis

## Cierny- Mader Classification/ Factors (1980's)

- **Location of infection in Bone:**
  - 1. Medullary
  - 2. Superficial
  - 3. Localized
  - 4. Diffuse
- **Type of Host:**
  - **“A”:** Healthy Host  
normal healing potential
  - **“B”:** Compromised Host  
Systemic or Local Factors  
+/- Correctable ??
  - **“C”:** Debilitated host:  
Treatment is worse than Disease

Cierny G, Mader JT, Pennick H. A clinical staging system of adult osteomyelitis. *Contemp Orthop*1985; 10:17 – 37

Mader JT, Shirliff M, Calhoun JH. Staging and Staging Application in Osteomyelitis. *Clinical Infectious Diseases*. 1997;25:1303–1309.

### • Systemic (s):

- Organ failure (renal, hepatic)
- Malnutrition,
- Diabetes Mellitus
- Chronic Hypoxia
- Extremes of Age
- Immune disease
- Immune compromise
- Malignancy

\* 2021\*  
Substance  
Abuse,  
Noncompliance

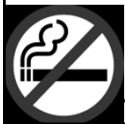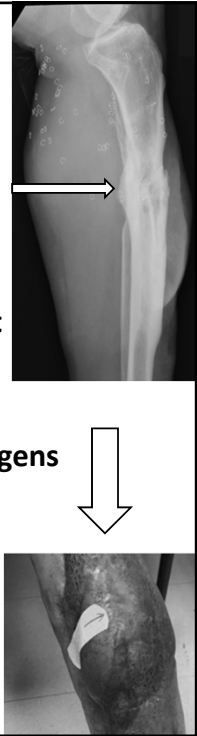### • Local (l):

- Vascular disease, stasis, lymphedema
- Scarring, radiation fibrosis
- Neuropathy
- Small vessel disease
- Tobacco abuse

## Treatment Strategies:

Wound Closure efforts may require any or all to succeed

- Recognize Source and remove Bioburden
  - Assessment, Imaging, Irrigation, Debridement, Bone Resection
- Protect bone
  - Avoid Further and Repeat contamination
  - Maintain or Restore Structural integrity of bone, joint, tendon, ligament
    - **May Require Advanced Orthopaedic Reconstruction**
  - Antibiotics: IV, Oral, Local delivery (beads), Antimicrobial dressings
  - Avoid spread: Coverage/ closure, Blood supply, Dressings, Control pathogens
- Optimize healing potential--Improve host
  - Oxygen, Nutritional resources for Healing,
  - Decrease Size of wound-, Negative pressure, Bone resection, Flap/Graft
- Address Soft tissue Issues
- Control Medical Factors (optimization)
- No Tobacco**



Late effects of open tibia plateau fracture: plain X-ray and CT showing foreign body, sclerotic dead bone, and defect

Plain x-ray: 2 stage reconstruction

MRI proximal tibia: showing metal artifact = wrong study!

**\*\*IMAGING USE IN CLINICAL SCENARIO \*\***



## General Surgery and Wound Care

---

**David Renton, MD, MPH, FACS**

*Associate Professor*

*Associate Chief Quality Officer for Perioperative Services*

*Department of Surgery*

*The Ohio State University Wexner Medical Center*

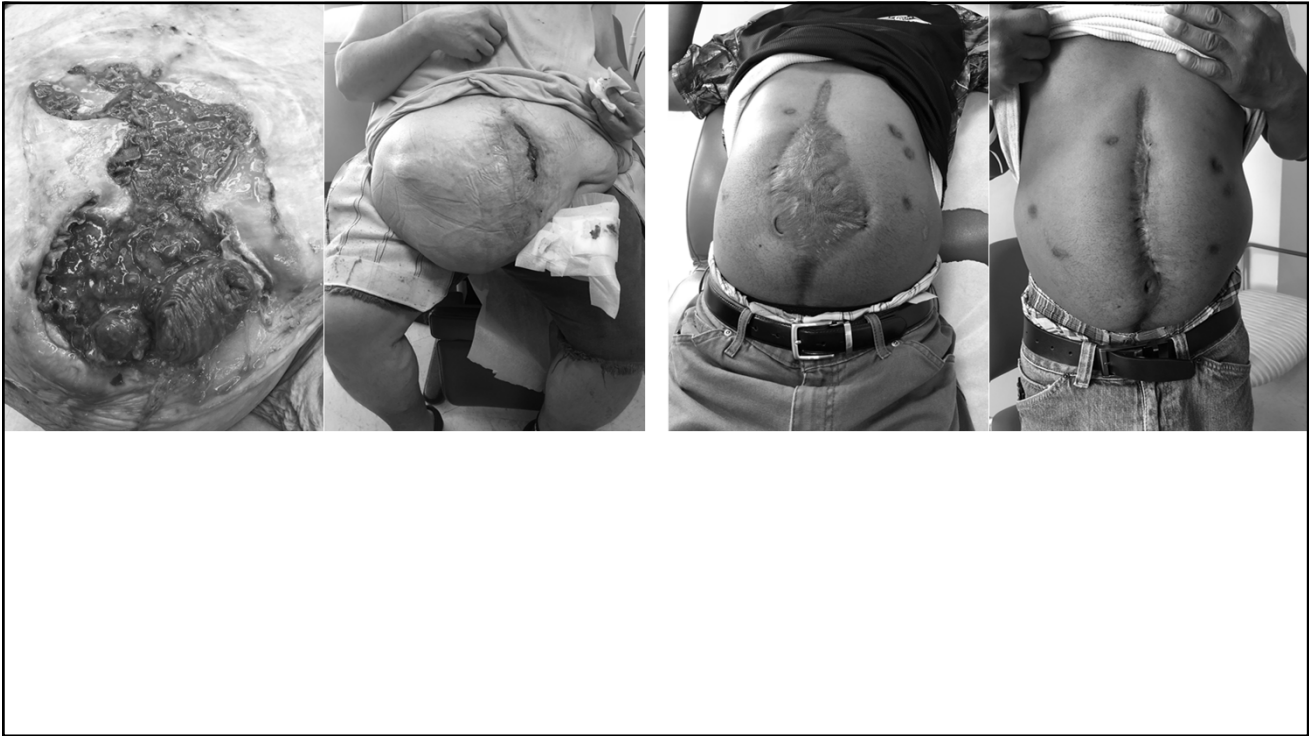**MedNet21**  
Center for Continuing Medical Education

 **THE OHIO STATE UNIVERSITY**  
WEXNER MEDICAL CENTER

## General Surgery and Wound Care

- Typically, General Surgery deals with the abdomen, so this is what we deal with in Wound Care as well
- Most of what I am seeing in wound care is chronic abdominal wounds
- This often has to do with infected prosthetics such as hernia mesh that are involved in patient care in the past
- Also help with colostomy creation for help in healing sacral wounds





## Laparoscopic Loop Colostomy

- Diverts stool to the abdominal wall through a stoma
- Helps clean up perineum, allows for complex wound closure of sacral wounds
- Can be temporary, or permanent, depending on patient preference

# Wound Care

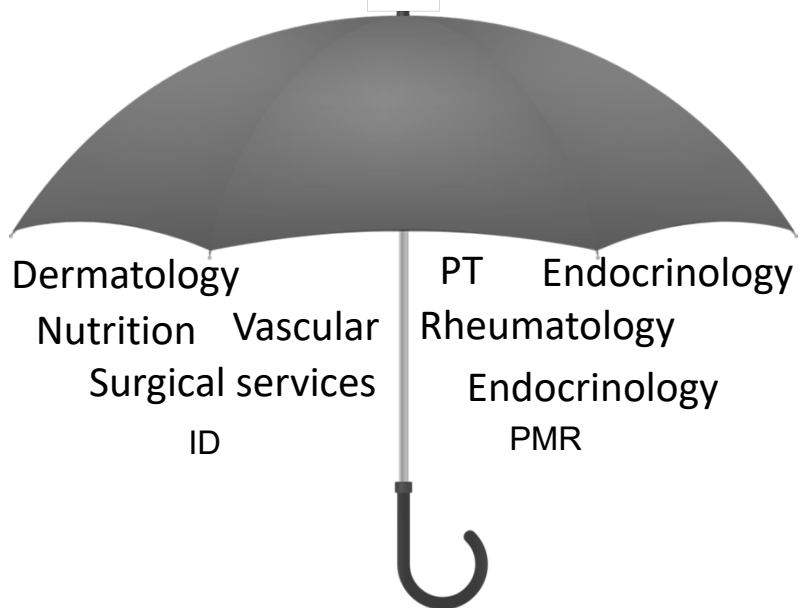
- With a team approach, we can offer our patients a full breadth of options for wound care
- Having Plastic Surgery, Orthopedics, and General Surgery gives patients the best chance of healing their wounds
- Our nursing staff is very experienced, and helps get patients ready for surgery if it is indicated.



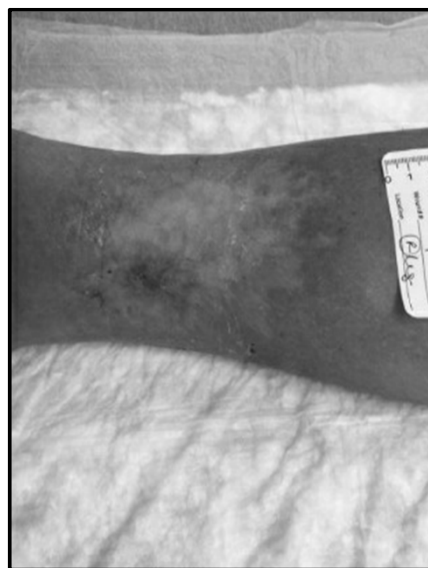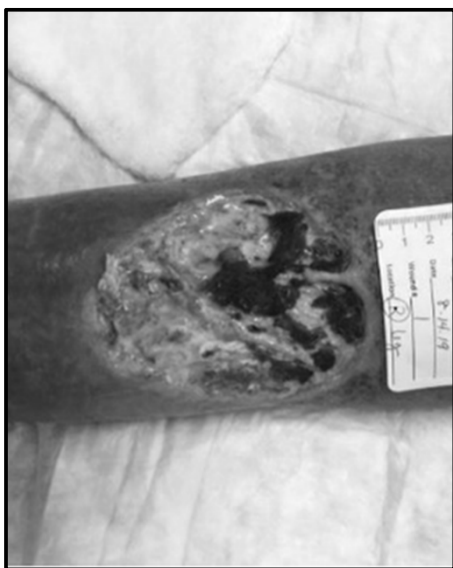## Case Presentations on Various Wound Etiologies

**Nancy Hale, APRN, CNP**  
*Comprehensive Wound Center*  
*The Ohio State University Wexner Medical Center*

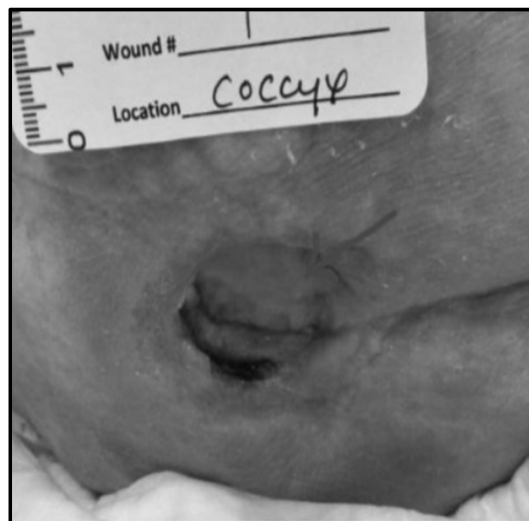
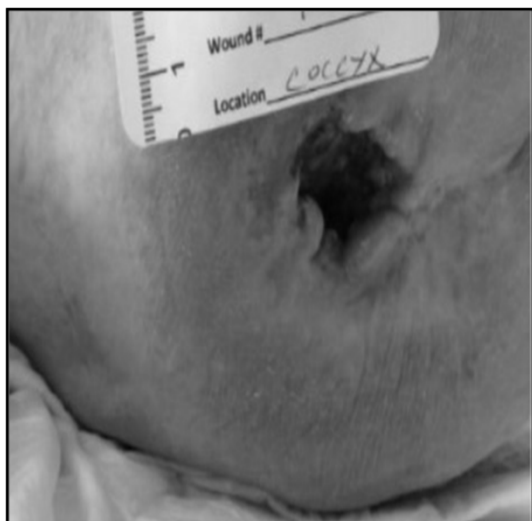
# Wound Center Provider



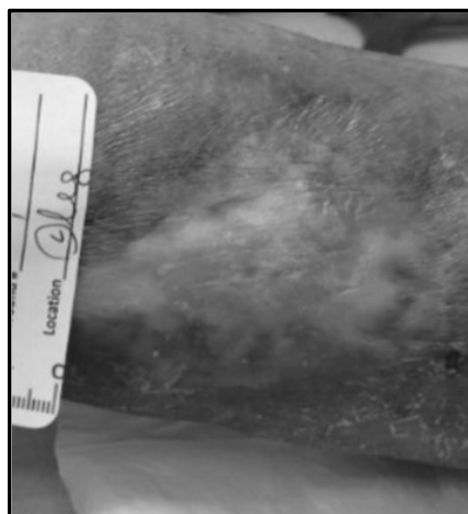
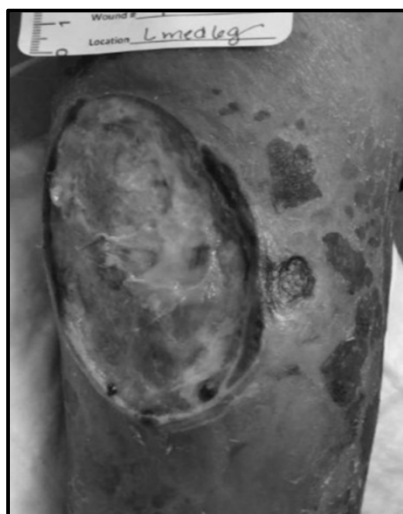
## Pyoderma



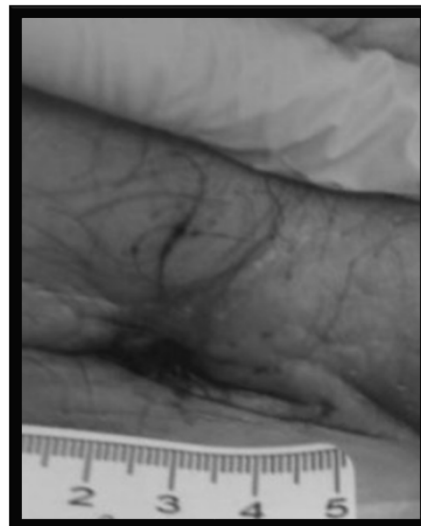
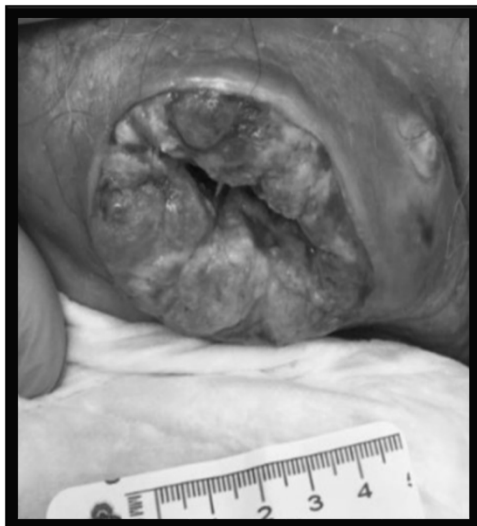### Stage 4 Pressure Injury



### Arterial Wound



## Malignant Melanoma



## Advanced Wound Care at the New OSU Wound Center

**Rajiv Chandawarkar, MD**

*Director of OSU WOUND CARE*

*Director Plastic Surgery, The Ohio State University Wexner Medical Center  
East Hospital*

*Professor of Plastic Surgery, Department of Plastic Surgery*

*The Ohio State University Wexner Medical Center*

**MedNet21**  
Center for Continuing Medical Education

 **THE OHIO STATE UNIVERSITY**  
WEXNER MEDICAL CENTER

# Disclosures

I have no disclosures

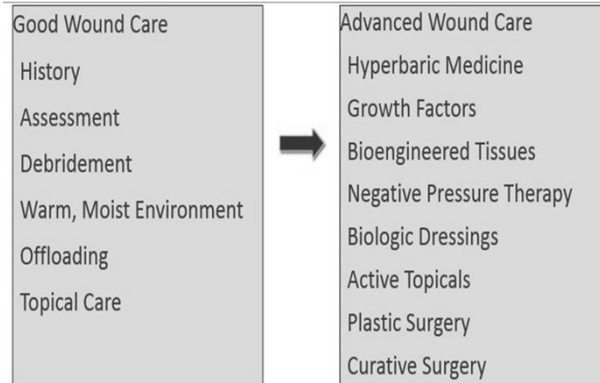
## **New OSU Wound Center What is Advanced Wound Care**

Wound care professionals should select the appropriate wound management system based on:

- 1) Published clinical evidence ;
- 2) Contribution to providing the best outcomes at the total lowest cost of care, and
- 3) Comprehensive multidisciplinary care model with highly specialized care.

We offer the most advanced treatment for nonhealing and hard-to-heal wounds, including hyperbaric oxygen therapy, surgical and microsurgical reconstruction, advanced use of biologics and new emerging technology

## Referral to Wound Center



## Wound Care Documentation

DESCRIBE WHAT YOU SEE!

**Note the percentages**

**Is there odor, is there pus, is there drainage?**

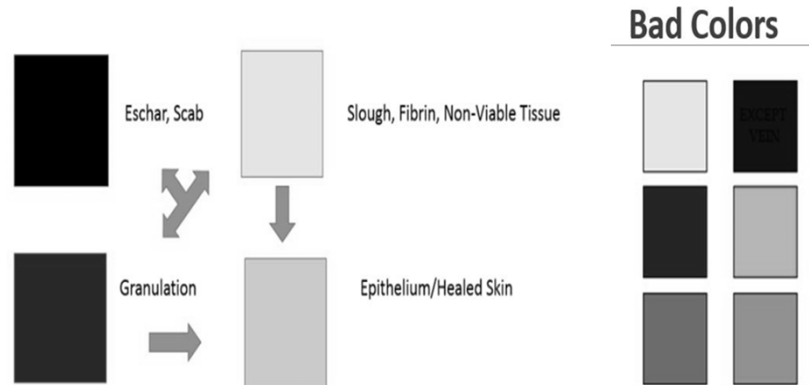
**Describe the periwound**

- Bleeding, moist, intact, red, hot, swollen, dry, cracked

**Note your intervention**

- What did you put on the wound?

# Color Coding Wounds



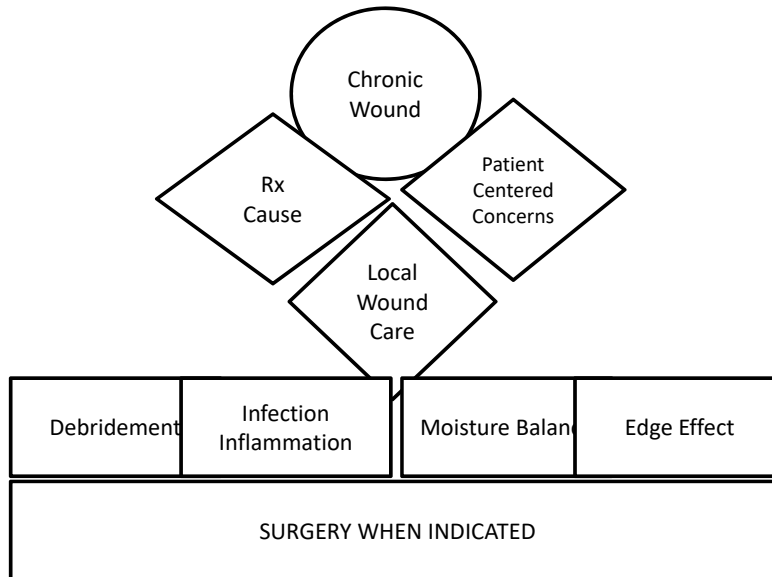
## New OSU wound care center

### Principles of Advanced Wound Care

- Differentiate between acute wounds and the development of chronic wounds.
- Identify risk factors for chronic wound development.
- Identify the four most common type of chronic wounds: pressure injury and venous, arterial, and diabetic ulcers.
- Discuss the development of biofilm and the role it plays in wound chronicity.
- Apply the concepts of DIME+S
  - Debridement, Inflammation Control, Moisture management, Edge effect AND Surgery (when indicated)



## New OSU wound care center Wound Preparation Model



## DEBRIDEMENT

### Why is it necessary?

Necessary to convert a chronic wound into an acute wound

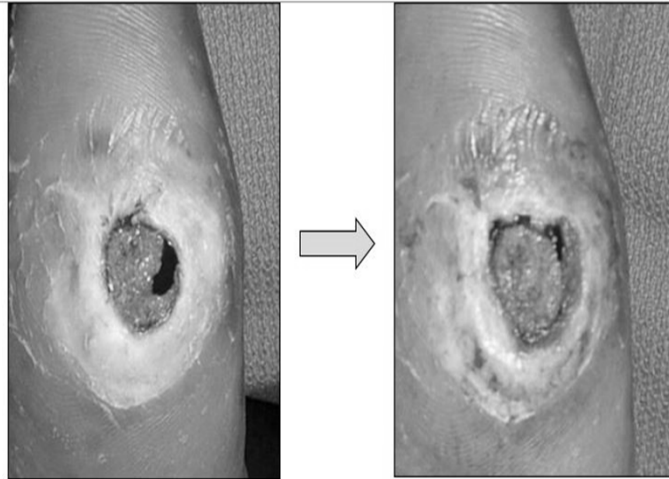
Keeps the wound in the active phases of healing

Removes nonviable/infected tissue and bioburden

Types of debridement: autolytic, enzymatic, sharp, mechanical

## DEBRIDEMENT

### Why is it necessary?

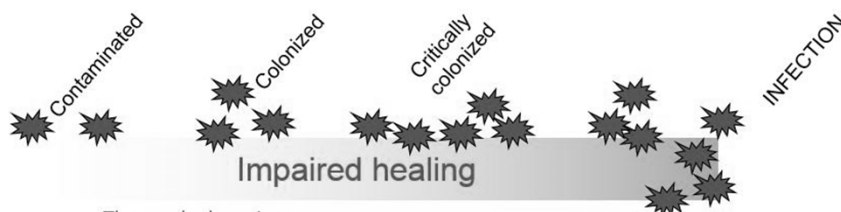


## Inflammation and Infection Control

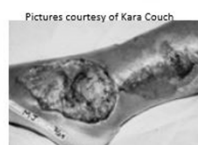
### What Does it Do?

Critically colonized	Deep wound infection	Systemic infection
Nonhealing	Size bigger	Fever
Exudative	Temperature increased	Rigors
Red and bleeding	Os (probes to or exposed bone)	Chills
Debris	New areas of breakdown	Hypotension
Smell	Exudate, Erythema, Edema Smells	Multiple organ failure
Tx: Topical	Systemic	Systemic

# Infection – shades of grey



- Thorough cleansing
- Debridement of necrotic tissue
- Exudate management
  - Consider topical antimicrobials
  - Silver dressing
  - Cadexomer iodine gel
- Systemic antibiotics



# Management of Moisture Tips and Tricks

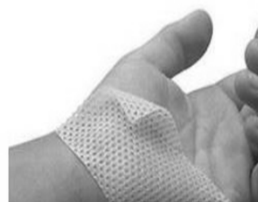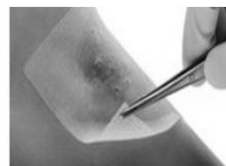

	Exudate amount			
	None	Small	Moderate	Large
■ Films	██████████			
■ Hydrogel	██████████	██████████		
■ Hydrocolloid		██████████	██████████	
■ Alginate			██████████	██████████
■ Foams			██████████	██████████
■ Specialty absorbent				██████████

## Edge Effect: The Benefits of a Contact Layer

Non-adherent, atraumatic

Porous mesh structure

Can stay on wound for many days, changing secondary dressing over contact layer



## Edge Effect: Choosing the Right Dressings

	Hydrogel	Honey	Foam	Alginate	Contact Layer
Epithelial	Dark	Dark	Dark	Light	Dark
Granulated	Dark	Dark	Dark	Dark	Dark
Exudative	Light	Dark	Dark	Dark	Light
Fibrin	Dark	Dark	Light	Dark	Light
Slough	Dark	Dark	Light	Light	Light
Eschar	Dark	Dark	Dark	Light	Light
Depth	Dark	Dark	Light	Dark	Light

\*\*\*Silver can be added into hydrogel, foam, alginate, and contact layer as needed.

\*\*\*Bordered foams can be used over hydrogels, honey, silver, alginate, contact layers.

# Overall Cost-Awareness

Complicated by many factors:

- Insurance coverage
- Quality of life
- Economic constraints
- Rising health care costs - labor and materials

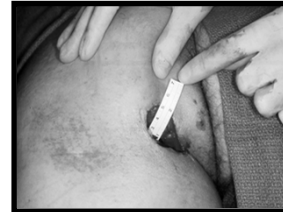Cheaper wound management does not necessarily = cost savings

- For example, if the dressing costs more but reduces time to wound healing, decreases length of stay, reduces the frequency of dressing changes, and/or decreases the need for analgesia with dressing changes, then it may actually mean overall cost savings

# Surgical Closure

## Pre-op Evaluation

- History:
  - Cardiac, pulmonary, endocrine, oncologic
- Location :
  - Depth, volume
  - Involvement of adjacent structures
    - Bone, Joint, sinus
- Quality:
  - Vascularity
  - Presence of scarring
  - Extent of infection
    - Cellulitis, Heavy bacterial count, C/S



## Pre-op Evaluation

- Nutritional status
  - Cachexia, anemia
- Musculoskeletal status
  - Spasms, fixed contractures
- Distant infection
  - Urinary, pulmonary, other
- General status
  - Neurologic/ psychiatric
    - Coma, disorientation
    - Schizophrenia, depression
    - Social support system

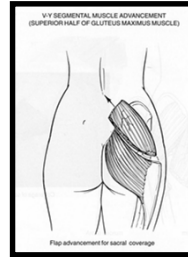
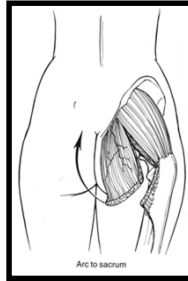
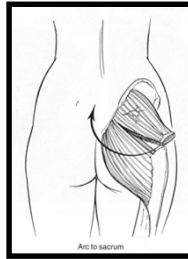
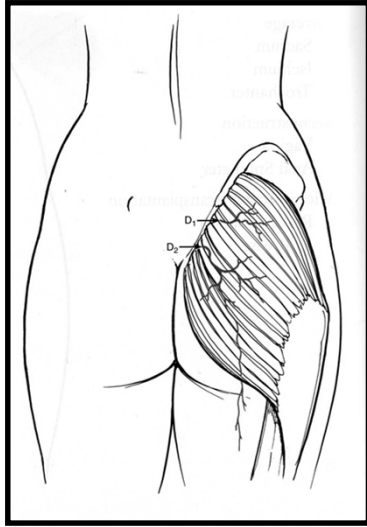
## Methods of Surgical Closure

- Primary closure
- Skin graft
- Pedicle flap: muscle, musculocutaneous, fasciocutaneous
- Free tissue transfer

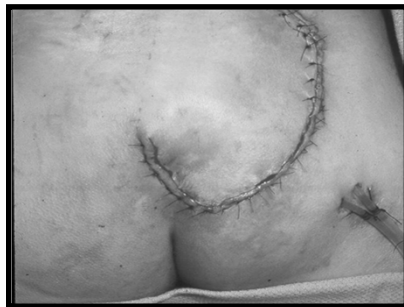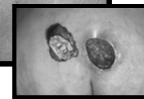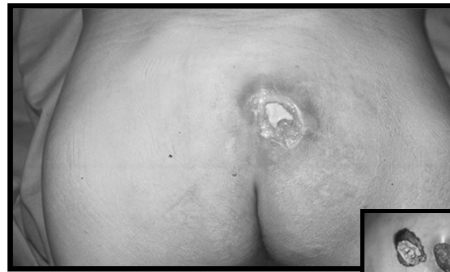## Sacral Ulcer Closure

- primary closure
- **superior gluteus muscle**
- gluteal fasciocutaneous
- gluteal turnover
- reverse dermal graft
- V-Y advancement
- paraspinous based perforator flap

# Gluteus maximus

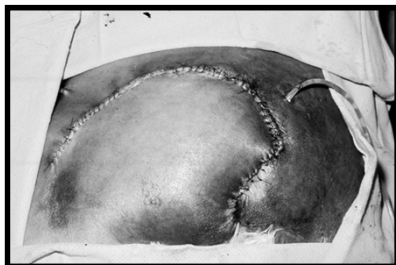
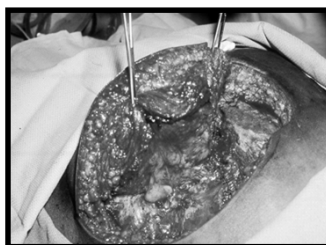
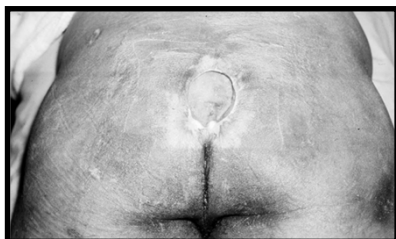


# Sacral Ulcer

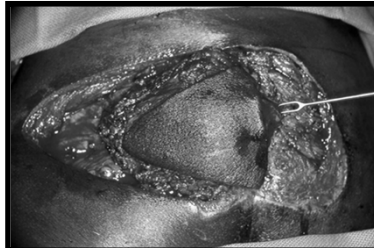
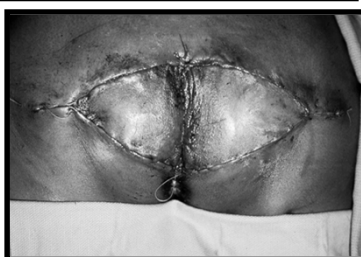
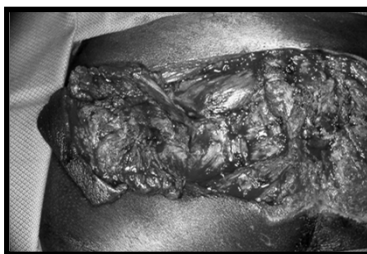
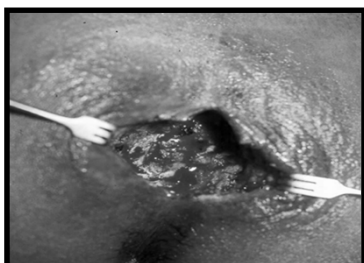

## Sacral Ulcer



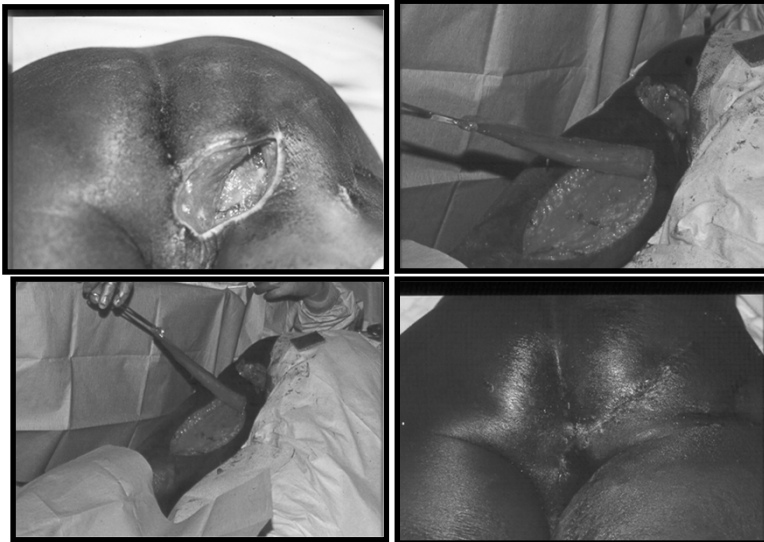## Sacral Ulcer



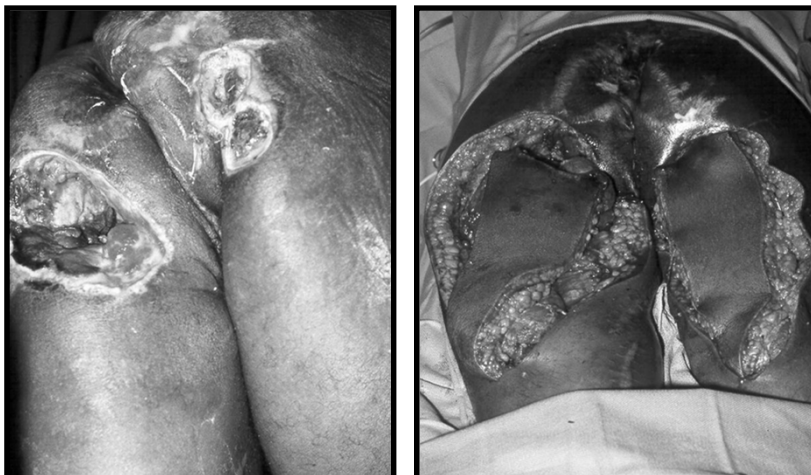# Ischial Ulcer Closure

- primary closure
- **posterior thigh**
- inf. gluteal muscle
- gracilis
- biceps femoris & skin
- hamstring
- **tensor fascia lata & vastus lateralis**
- lateral thigh
- rectus abdominus

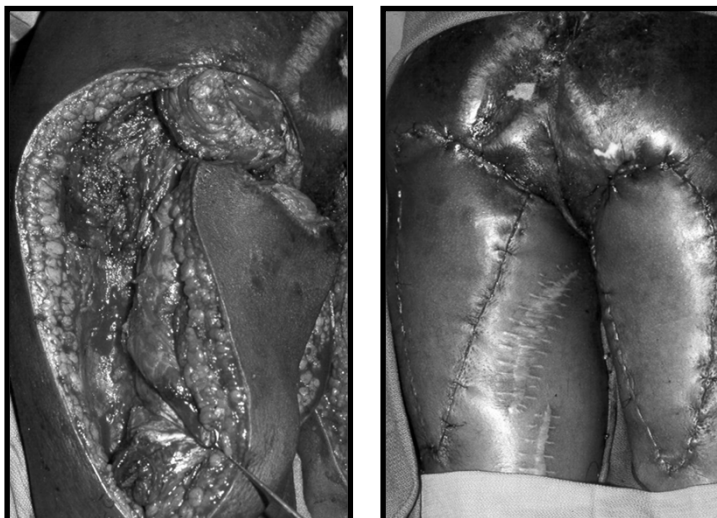
Ischial Ulcer

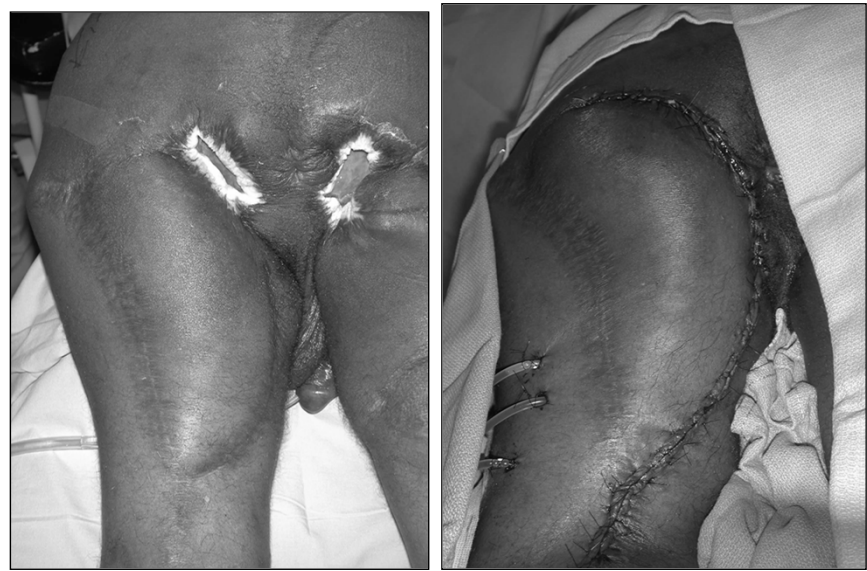
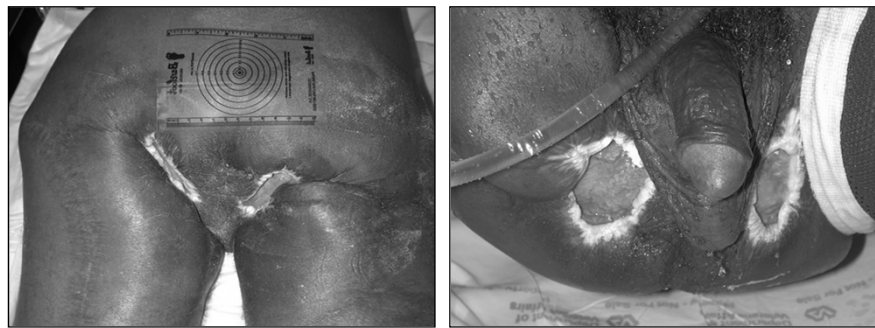
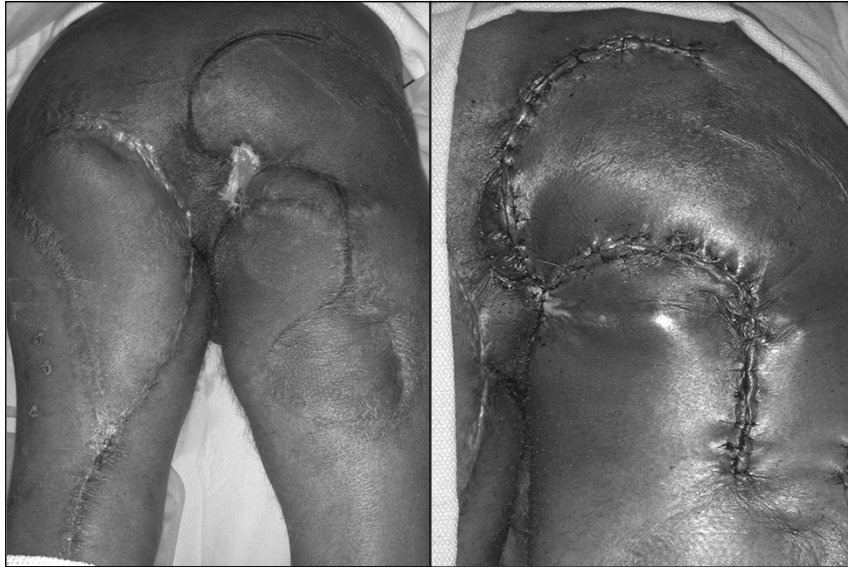## Ischial Ulcer



## Ischial Ulcer



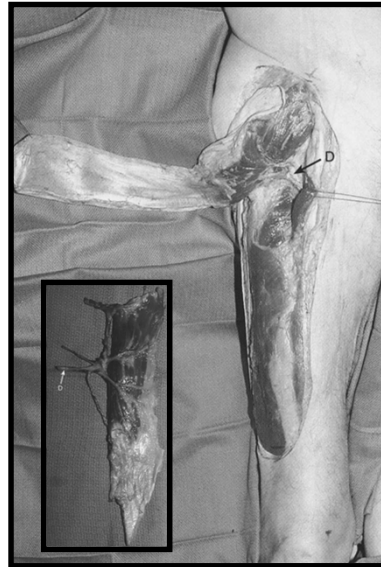
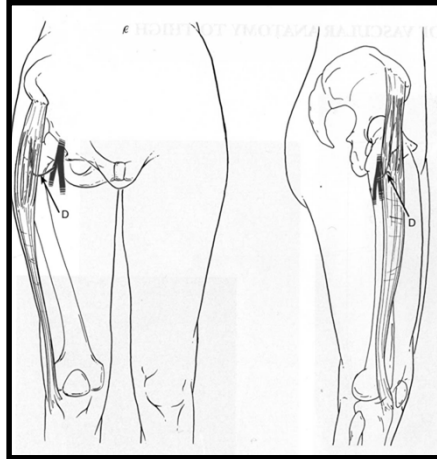




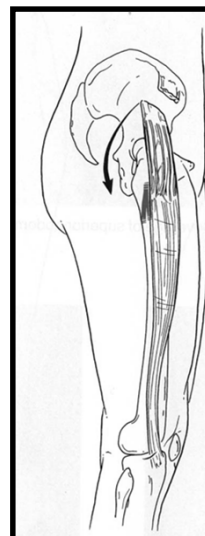
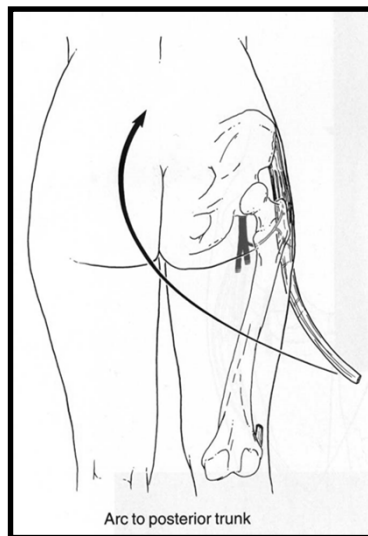
## Trochanteric Ulcer Closure

- random fasciocutaneous
- **TFL**
- TFL V-Y
- sensate TFL
- TFL w/ skin island
- gluteus medius & TFL
- vastus lateralis
- gluteus maximus, distally based
- gluteal thigh flap
- expansive gluteus max.

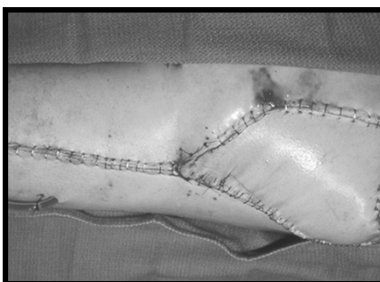
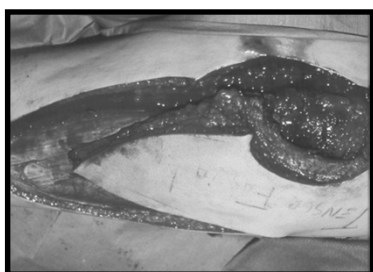
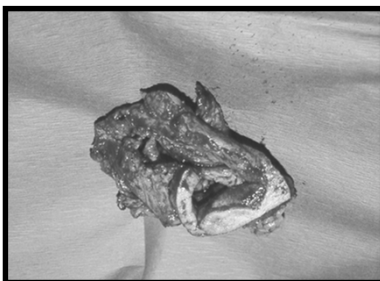
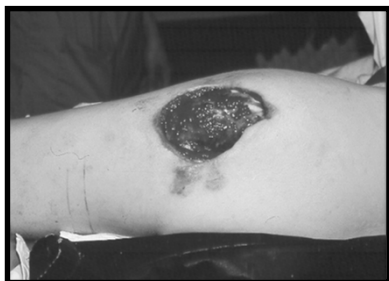# Tensor Fascia Lata (TFL)



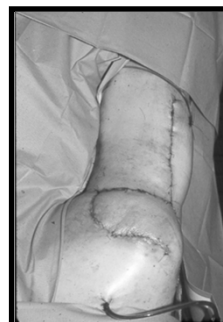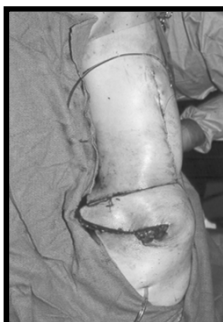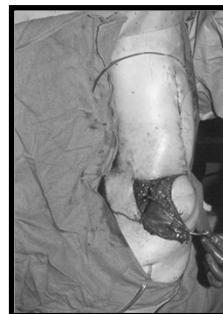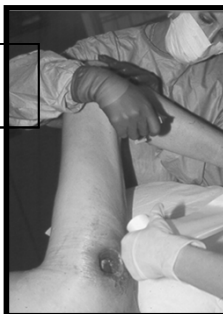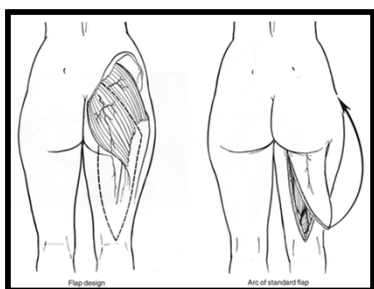
# Tensor Fascia Lata (TFL)



# Trochanteric Ulcer



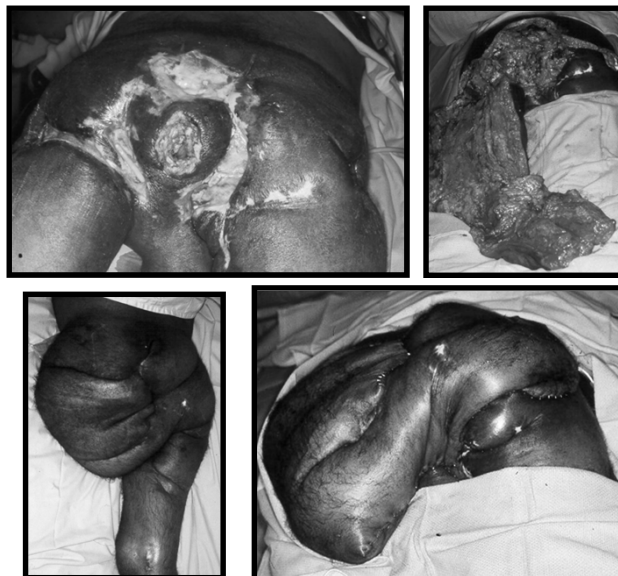# Posterior thigh flap



## Fillet (Leg Amputation) Flap

- Hip disarticulation & fillet flap
- High complication rate - OR blood loss, infection, sinus tract, dehiscence, femoral stump rotation
- Hemiacroporectomy: For extensive infection, very morbid

### Fillet (Leg Amputation) Flap





# **What does 'FUNCTIONAL RESTORATION' mean?**

## **Functional Restoration The FIVE CARDINAL QUESTIONS**

**Can the patient ambulate easily?**

**Can she/he resume their original work? If not can they find new work suitable to their 'NEW' limb function?**

**Is the reconstruction robust enough for continued wear and tear?**

**Are recurrence rates of diabetic foot wounds lowered?**

**Is the patient able to manage his diabetic target organ disease?**

# Functional Restoration The FIVE ESSENTIAL TOOLS

Accurate functional preoperative assessment

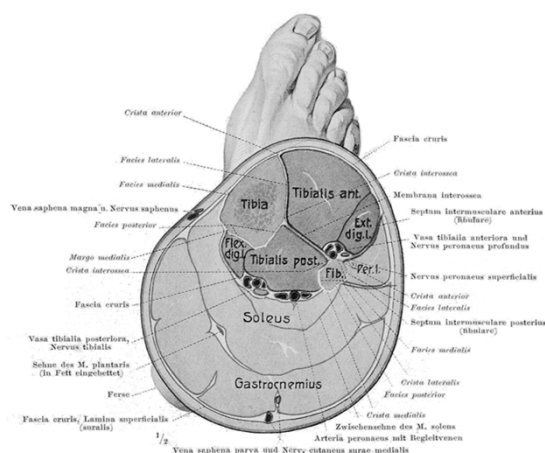
Diabetic (and other comorbid) control

System Structures: *The Iceberg Metaphor*

Well-defined Surgical Plan

Acute Postoperative Management

## SURGICAL PLAN: Reconstructive Choices Are A Plenty

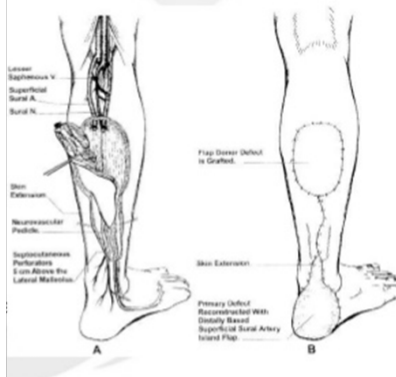


11 muscles, abundant adipofascia, three blood vessels, multiple perforators, superficial, deep and venae comitantes, one expendable bone.  
Coupled with great orthotics, and the ability to supercharge

# Functionalized Reverse Sural Fasciocutaneous Flap

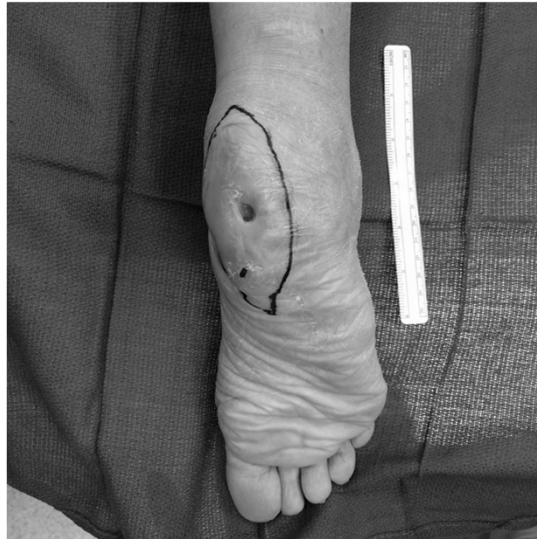## Reverse Sural FascioCutaneous Flap

- Sural And Saphenous Vessels
- Vasanevrosom and Vasovosorum may play a role (controversial)
- Deep fascia is included
- Great for Achilles Repair

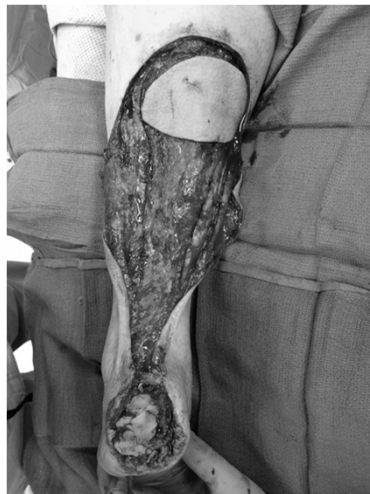

coverage

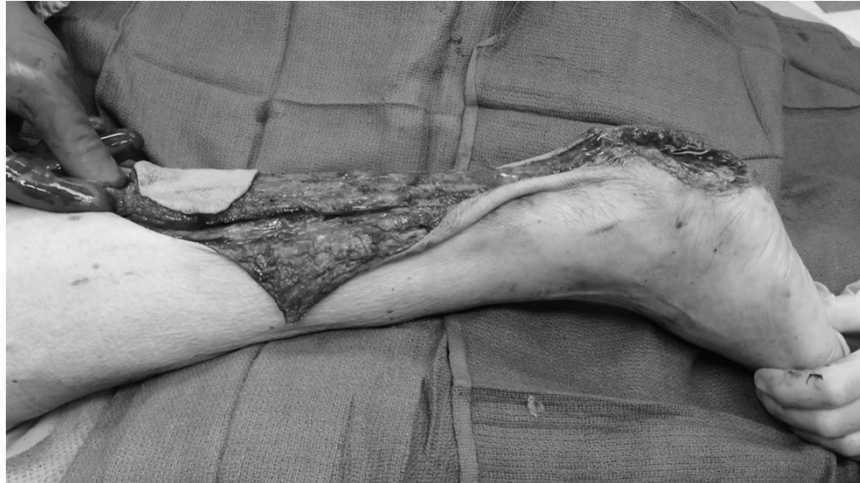## **Funtionalized Reverse Sural Fasciocutaneous Flap**



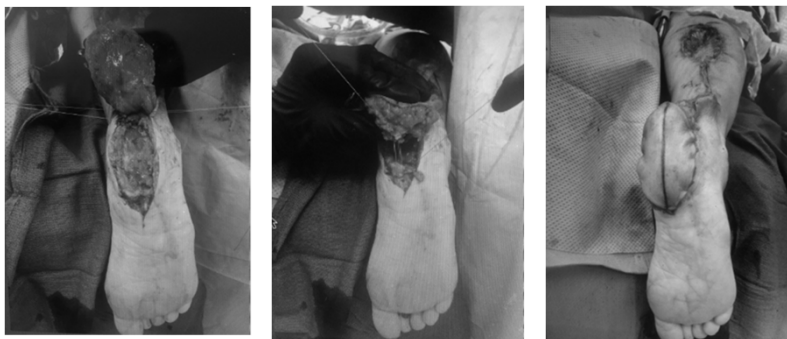## **Funtionalized Reverse Sural Fasciocutaneous Flap**



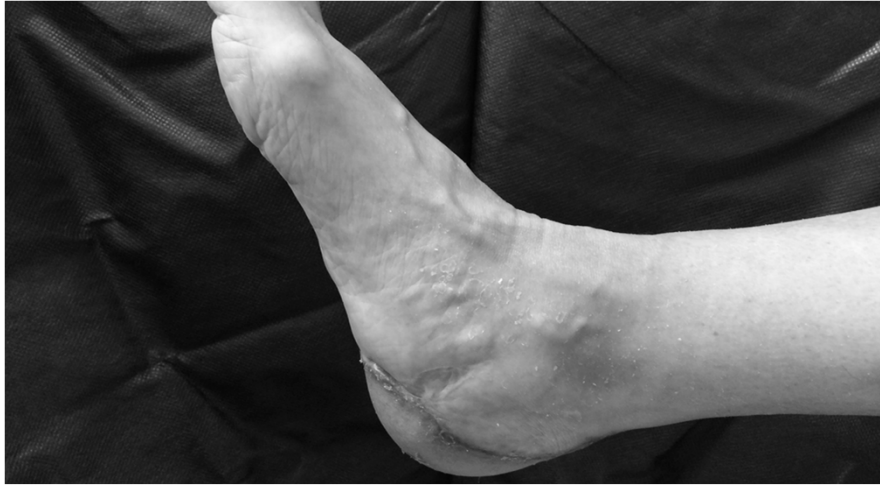## **Funtionalized Reverse Sural Fasciocutaneous Flap - Transfer**



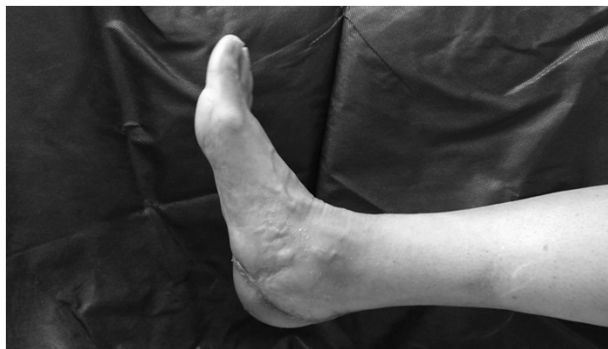## **Funtionalized Reverse Sural Fasciocutaneous Flap - Inset**



## **Funtionalized Reverse Sural Fasciocutaneous Flap**



## **Funtionalized Reverse Sural Fasciocutaneous Flap**



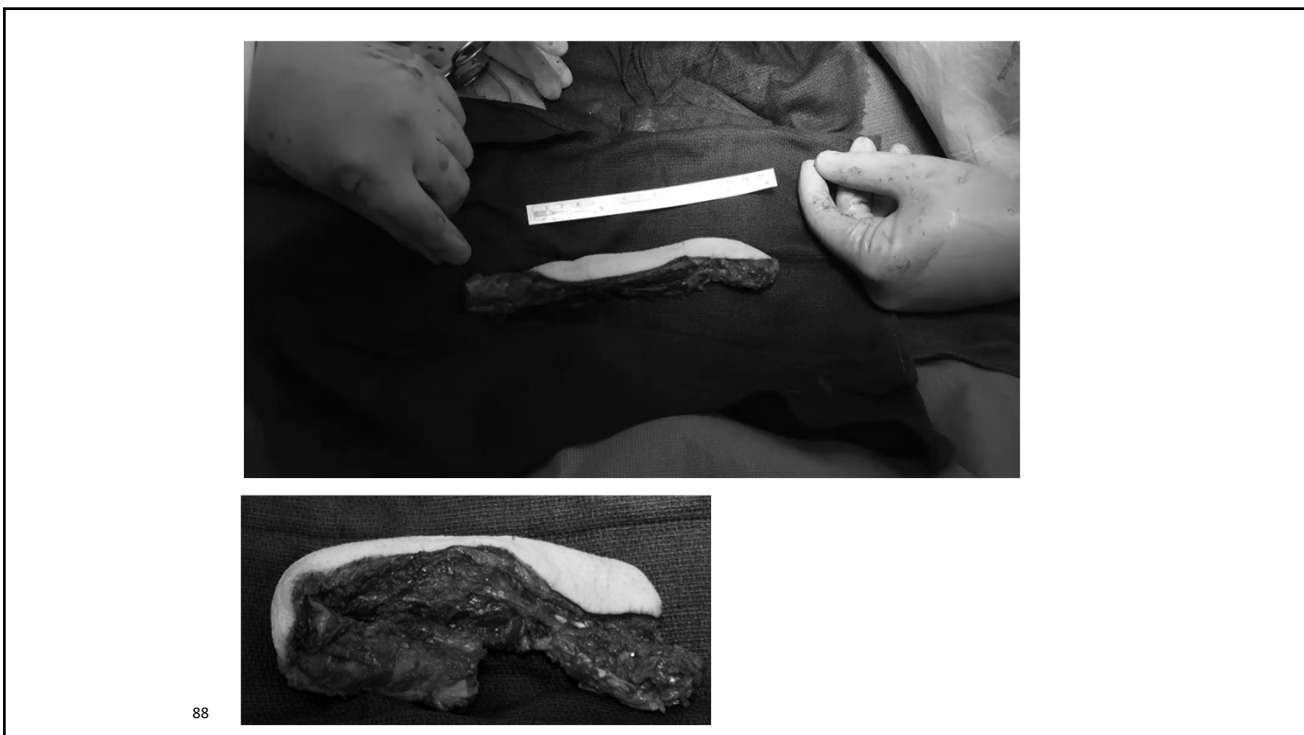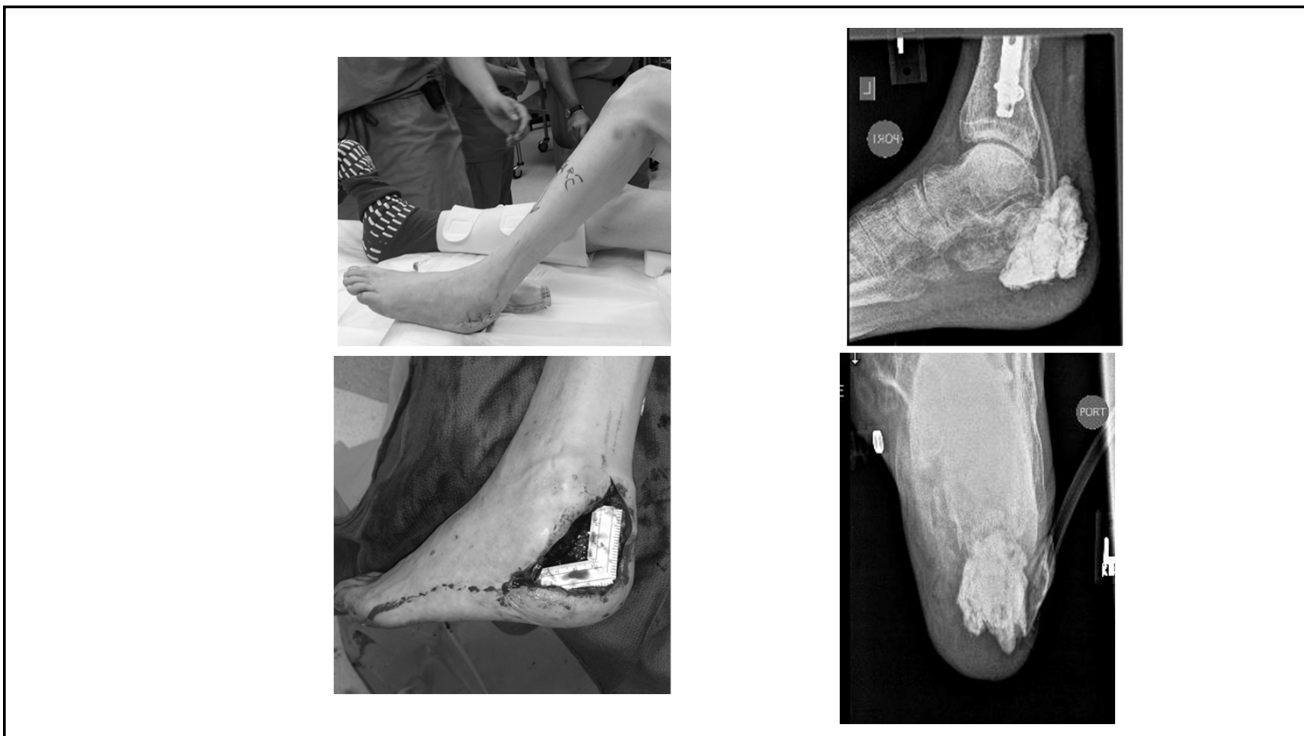
Currently, this patient walks without support, drives, and has resumed her job as a school teacher

# **Calcaneal reconstruction with microvascular double/single barrel fibula osteocutaneous flap**

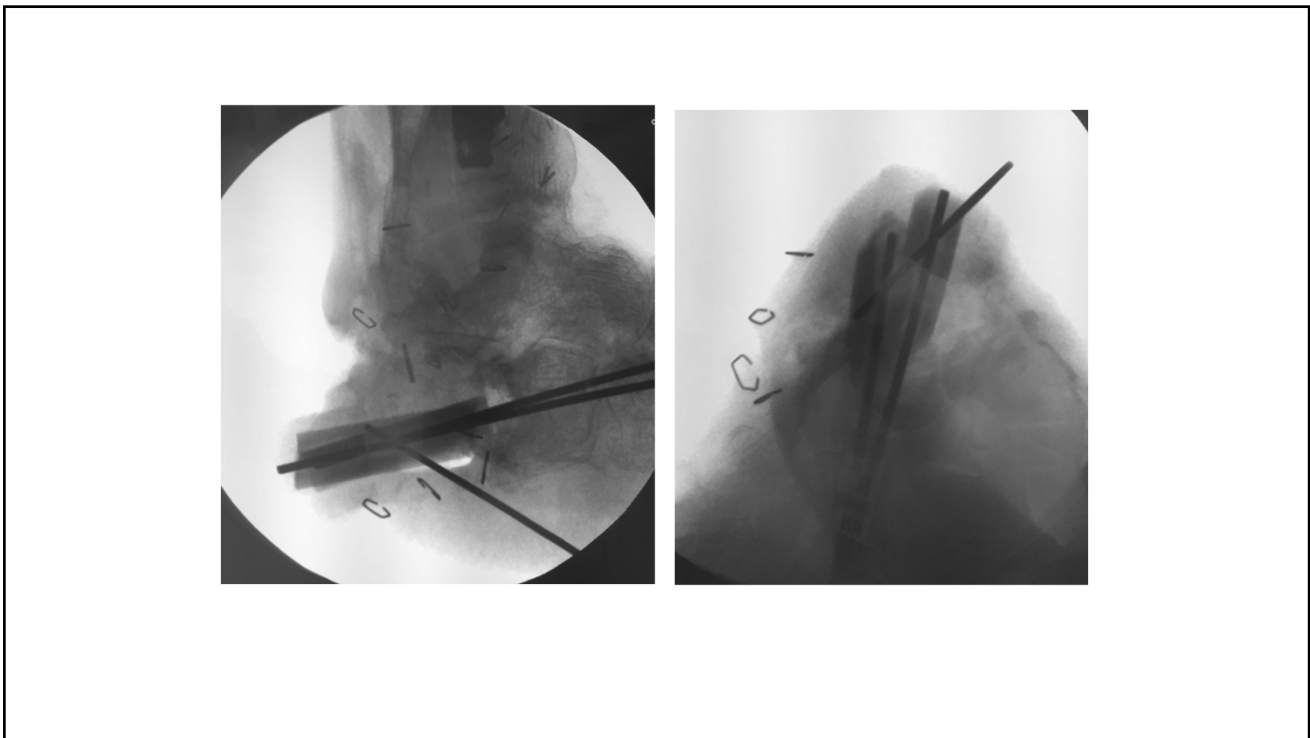
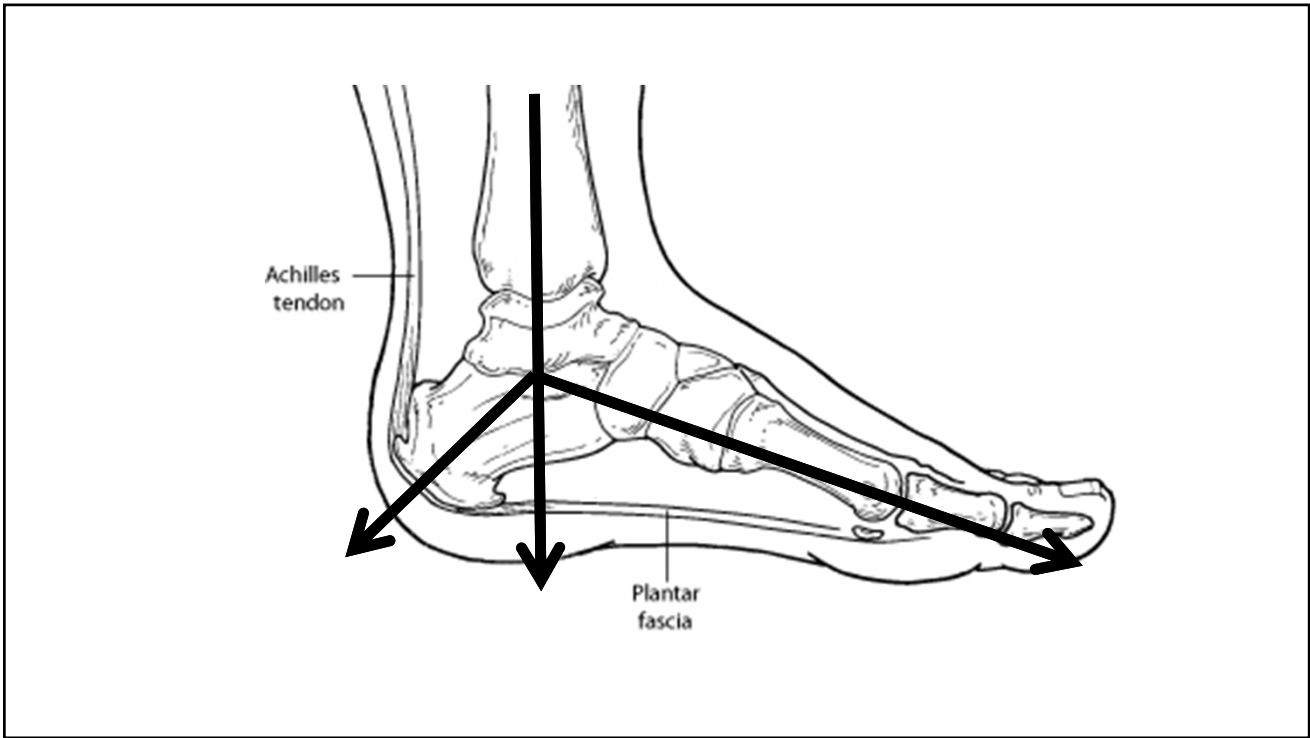
## **Background**

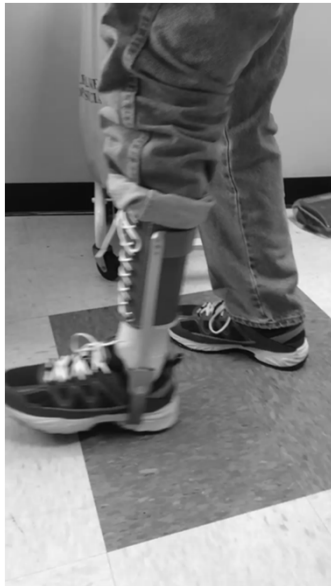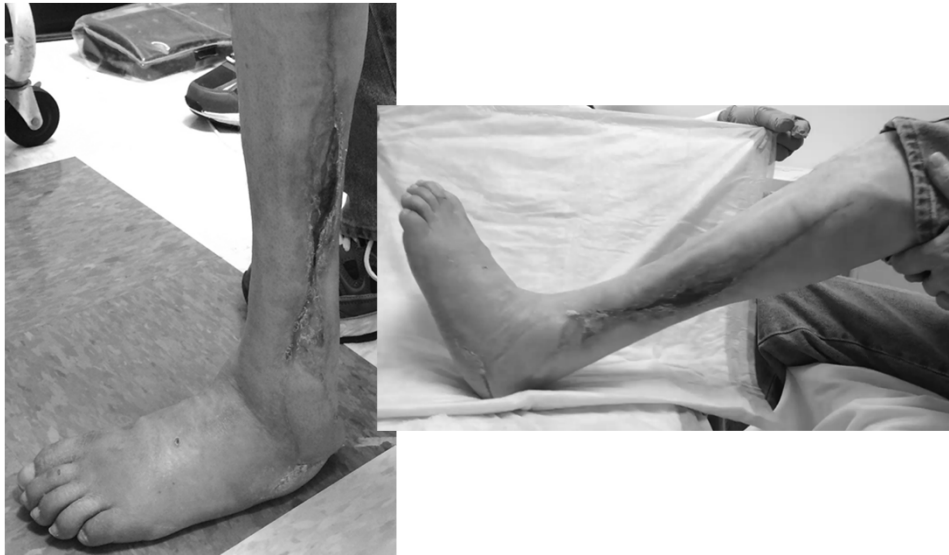Calcaneal destruction commonly occurs in diabetics - usually necessitates a below-knee amputation since the central weight-bearing mechanism is lost and reconstructive choices are limited.

Here we present two cases of calcaneal reconstruction, using double/single-barreled fibular osteocutaneous free flaps.

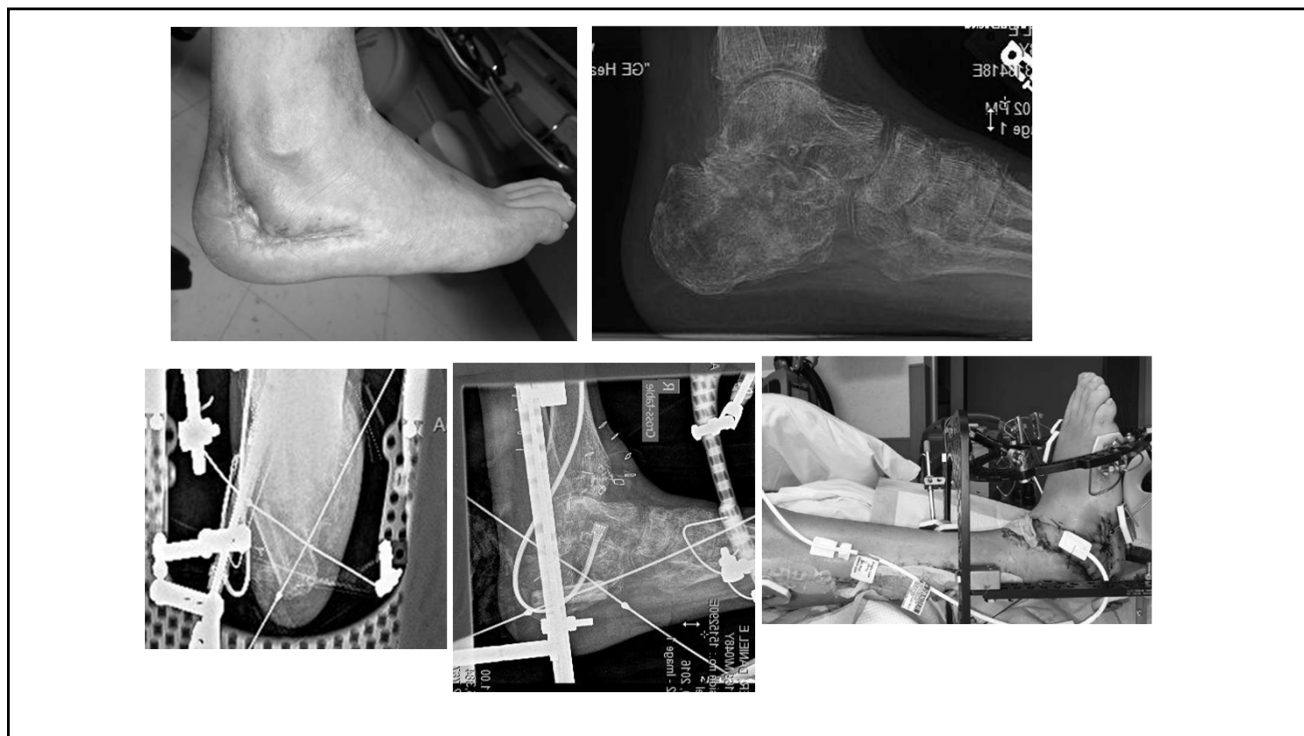






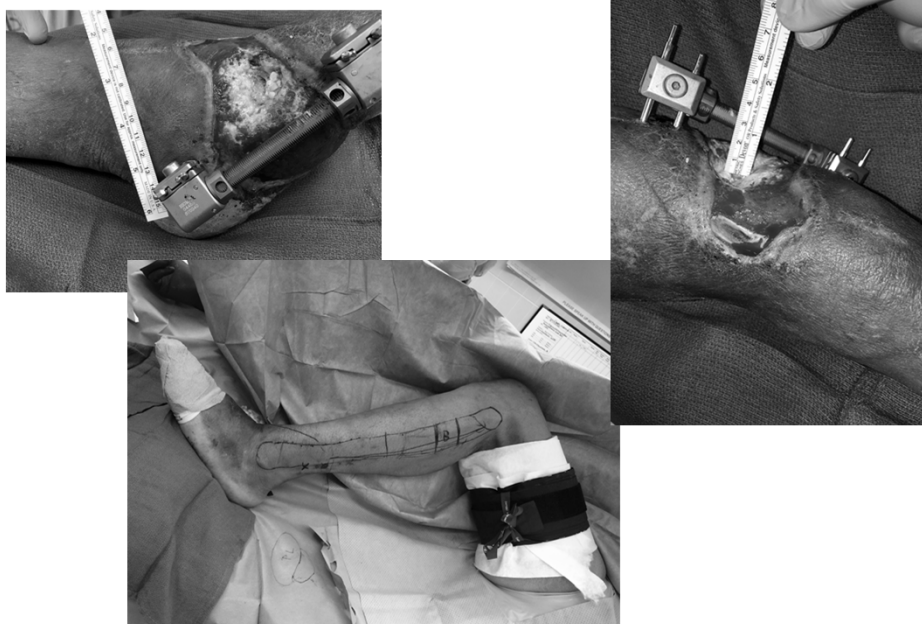

Currently, this patient walks without support and has resumed his job as a supervisor in a tree-cutting agency



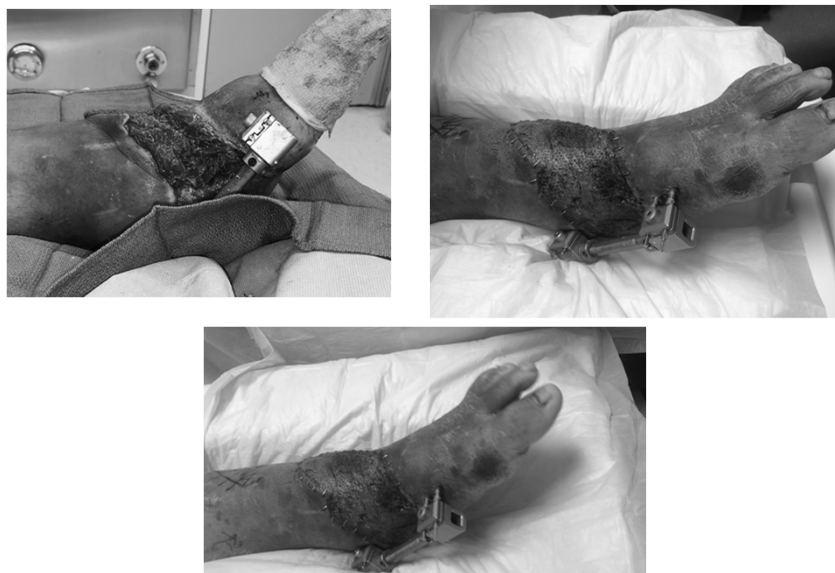Currently, this patient walks without support and has resumed his job as a short-distance truck driver. He even takes his Harley out, once in a while!

## Reverse Peroneus Brevis Flap



95

## Reverse Peroneus Brevis Flap



96

## **New OSU wound care center**

- Strong commitment by the members of the multidisciplinary team
- Physical space and financial support from the sponsoring institution
- Performance metrics, Quality measures
- Data Management and Support
- Technology
- Partnership with an OutPatient Community
- Actionable Knowledge
- CoMarket Expansion
- Defined Drivers of Care and Patient Volumes